



Altered Mental Status and a Rash



Dallin Mitchell DO

Carl R. Darnall Army Medical Center, Fort Hood, TX

Case History

A 61-year-old man from central Texas presented to the emergency department in the late summer with diplopia. Pt states he has also been experiencing intermittent fevers and headaches for over a week. He describes a delay in seeking medical care because he lives "far out in the country". During his stay in the emergency department he became increasingly altered and agitated and eventually required intubation. During admission in the medical intensive care unit, he developed a diffuse rash as pictured.

Imaging studies to include CT/CTA head and MRI brain were unremarkable. EEG showed "slowing", but no seizure activity. Initial CSF was clear with elevated opening pressure. Protein and glucose were also elevated with moderate increase in WBCs. Additional CSF studies pending.

Questions

1. What historical evidence when paired with the obtained imaging and testing can aid in raising your suspicion for the likely diagnosis.?
2. What laboratory test will ultimately confirm this patient's condition?

Answers

1. The development of encephalitis in an endemic area with CSF studies showing a pleocytosis and elevated opening pressure should raise suspicion for neuroinvasive West Nile Virus.
2. West Nile Virus is definitively diagnosed by a positive WN virus IgM antibody on ELISA. CSF testing should also take place in patients with neurologic symptoms and will also show West Nile IgM.

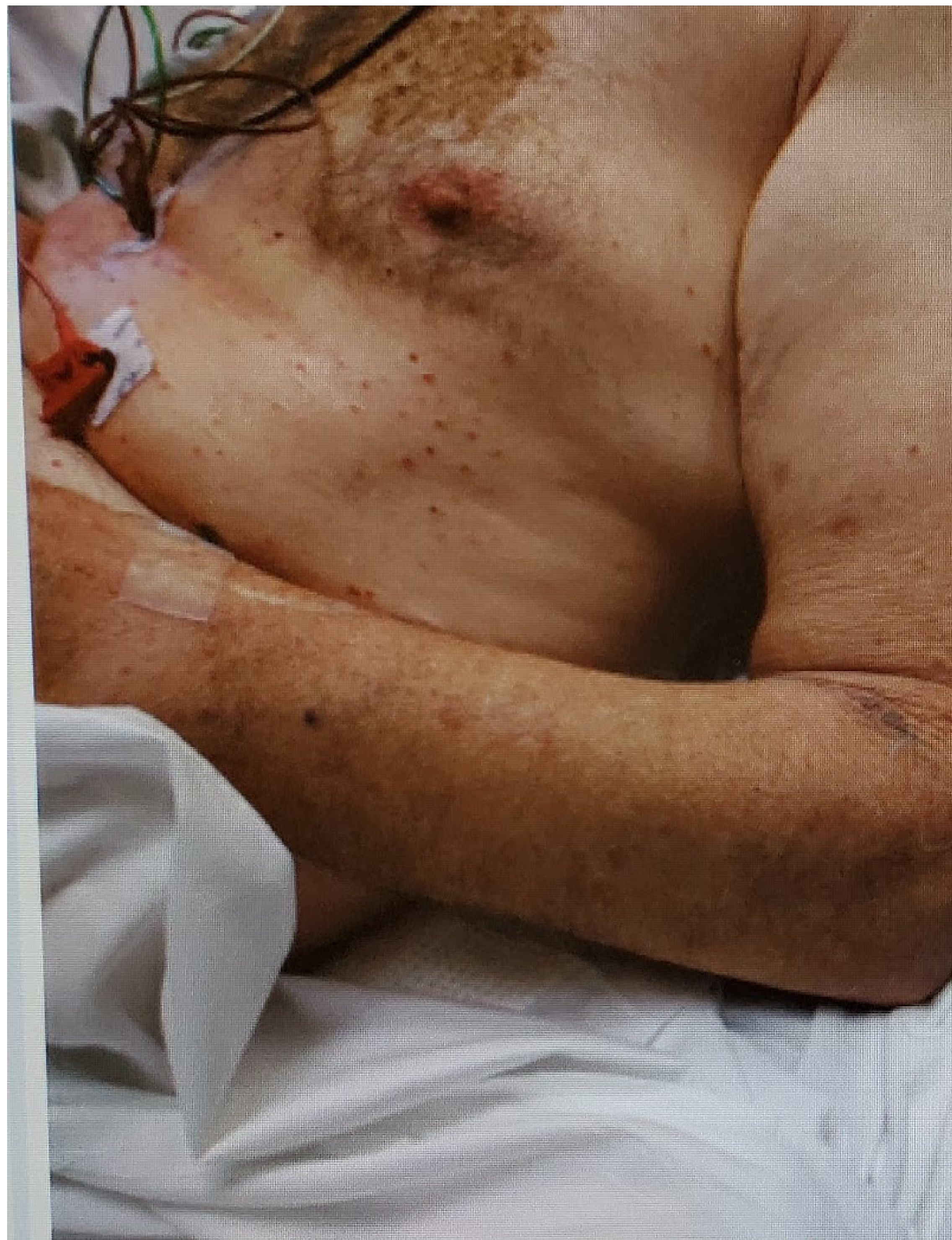

Image 1: Chest

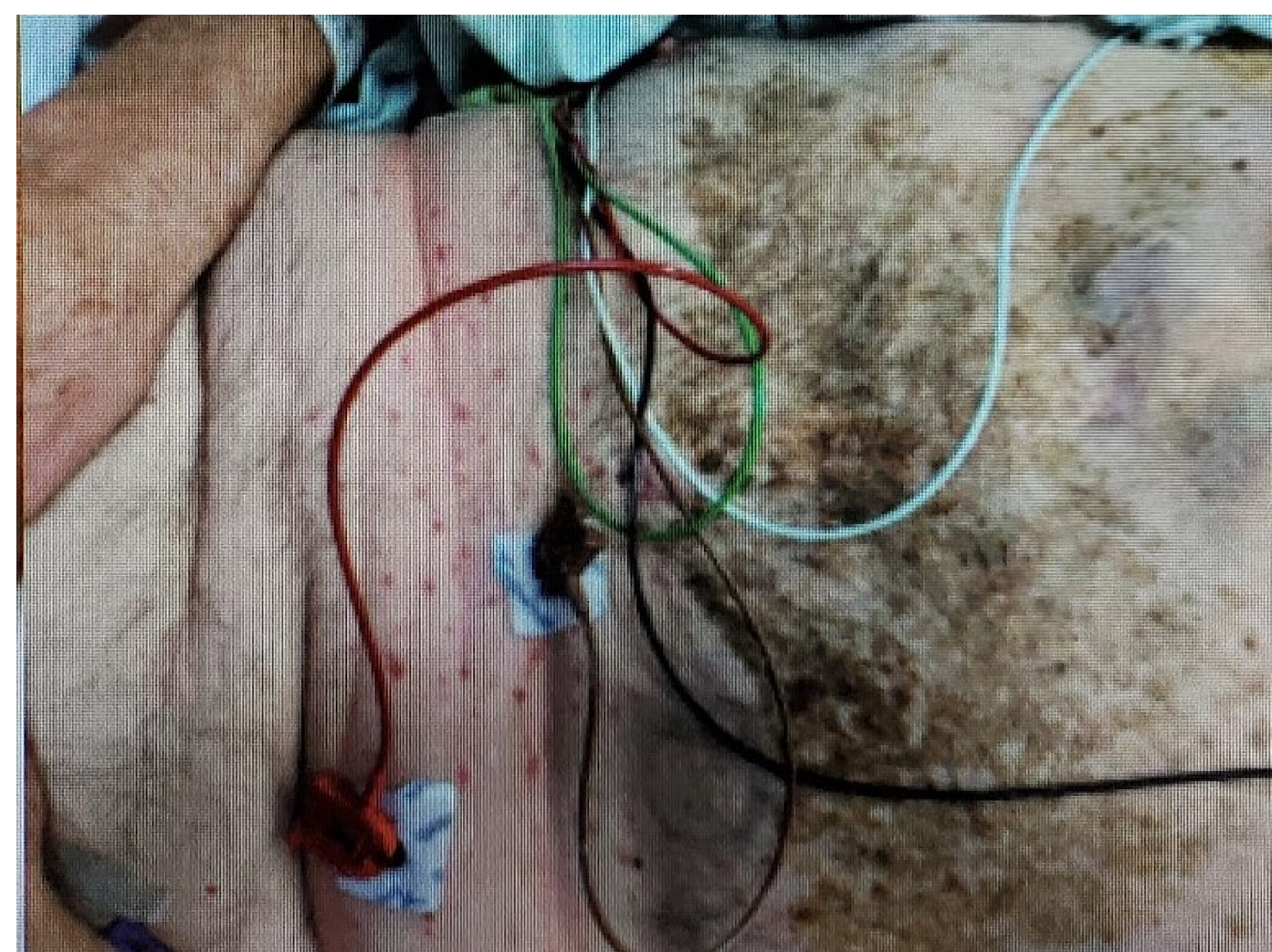


Image 2: Abdomen

Discussion

This is case of encephalitis secondary to neuroinvasive West Nile Virus. After the diagnosis was confirmed the patient was treated with acyclovir and corticosteroids. Later in the course, however, all nephrotoxic agents were stopped after he developed acute renal failure. After three weeks of cardiorespiratory support, the patient improved and was successfully extubated. He was discharged to a skilled nursing facility for rehabilitation and is expected to regain most function. The rash as shown in the picture is characteristic of disease, but is only present in 25 to 50 percent of cases. Advanced age is the most significant risk factor for the development on neuroinvasive disease.

Pearls

- West Nile Virus is distributed throughout the world and is predominately transmitted by bites from a mosquito. Have a raised suspicion for this diagnosis in months in which mosquitos are active.
- Although most infections are asymptomatic, advanced age increases susceptibility of development of West Nile fever and neuroinvasive disease.
- CSF studies are non-diagnostic but increased opening pressure, elevated protein, and pleocytosis with lymphocyte predominance should raise suspicion and prompt WV ELISA testing.

References

Grant L Campbell, Anthony A Marfin, Robert S Lanciotti, Duane J Gubler. West Nile virus, The Lancet Infectious Diseases, Volume 2, Issue 9, 2002, Pages 519-529, ISSN 1473-3099, [https://doi.org/10.1016/S1473-3099\(02\)00368-7](https://doi.org/10.1016/S1473-3099(02)00368-7).

Acknowledgement

The views expressed in this poster are those of the author(s) and do not reflect the official policy of the Department of Army, Department of Defense, or U.S. Government.